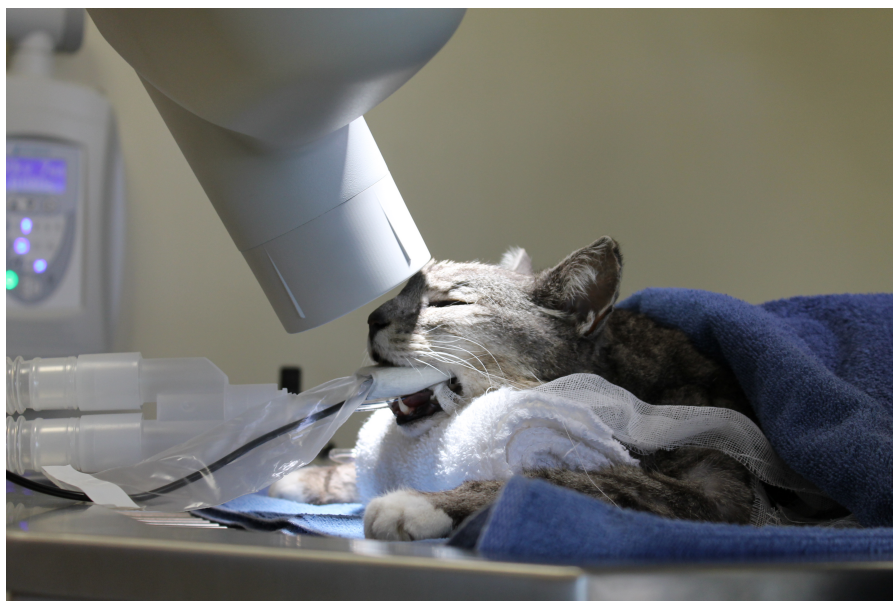

Midmark AcademySM

Continuing Education for the
Veterinary Professional



Radiographic Positioning Guide



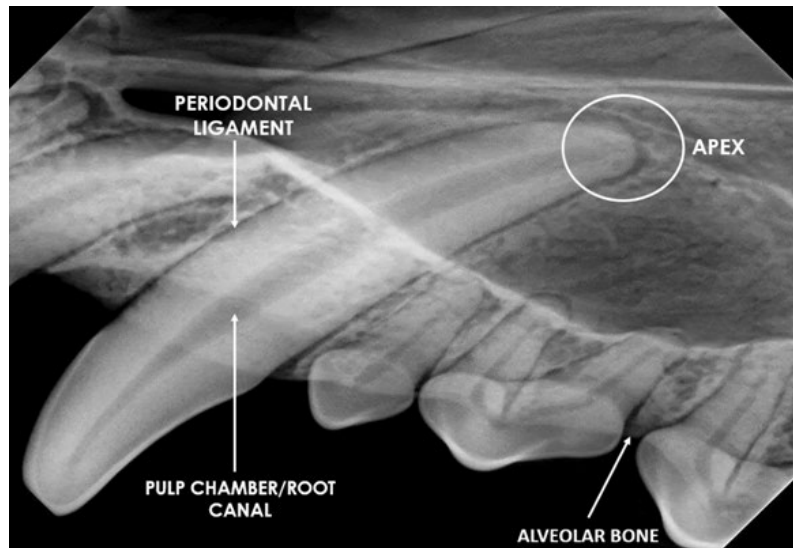
[midmark.com](https://www.midmark.com)

© 2023 Midmark Corporation, Versailles, Ohio USA
MKT-00416


midmarkTM
Designing better care.

DENTAL RADIOLOGY TIPS

To properly evaluate a dental radiograph image, you should be able to visualize the following areas:



Tube Head Angles for Canine Views

(Maxilla in sternal recumbency, mandible in lateral recumbency)

Maxillary Incisors and Canines - 60 degrees

Maxillary Premolars One, Two and Three - 45 degrees

Maxillary Fourth Premolar and Molar One and Two - 50 degrees

Mandibular Canines and Incisors - Parallel Technique

Mandibular Premolar Three and Four, Molar One, Two and Three - Parallel Technique

Mandibular Premolar One and Two - 25-30 degrees up from parallel to sensor

Tube Head Angles for Feline Views

(Maxilla in sternal recumbency, mandible in dorsal recumbency)

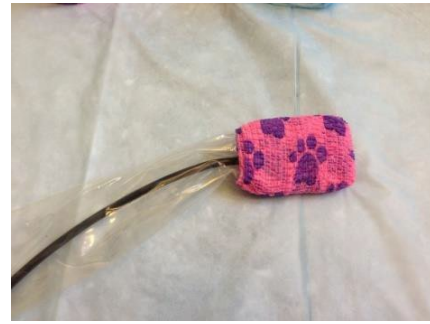
Maxillary Canines and Incisors - 60 degrees

Maxillary Cheek Teeth - 30 degrees

Mandibular Canines, Incisors, Premolar Three and Four - 70 degrees

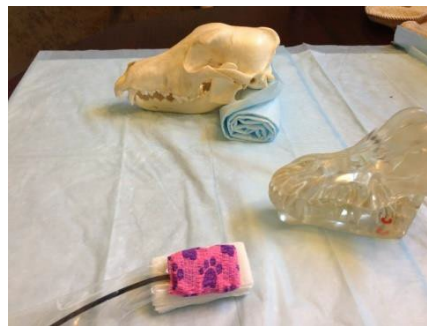Mandibular Molar - Parallel Technique

Wrap 3 inches of Vet Wrap around your sensor to provide cushion as well as extra gripping on the tooth for sensor stability. You may want to mark the working surface of the sensor with a sharpie to differentiate the top from the bottom of the sensor. The Vet Wrap will be placed over the sensor sheath.

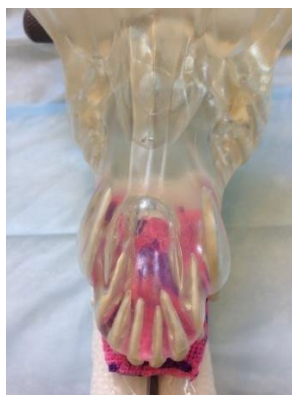

When doing canine or feline maxilla views to ensure consistent bisecting angles from patient to patient, the palate must be parallel to the table. For canine patients, roll a towel and place under the chin. For feline patients, use smaller items to achieve this.

There is a bisecting angle for every view in the canine and feline maxilla. These angles will be consistent from patient to patient as long as the palate is parallel to the table.

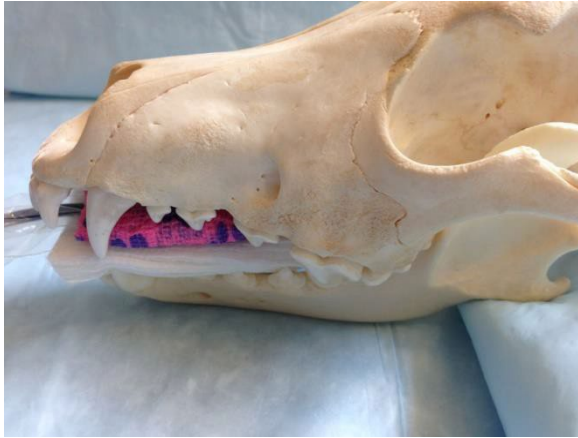


To image the alveolar bone to the apex of the tooth root, place the tips of the crowns on the edge of the sensor. This is typically what images you take to evaluate. If a tooth is discolored or fractured, then it is necessary to see the tip of the crown to the tip of the apex on the radiograph.

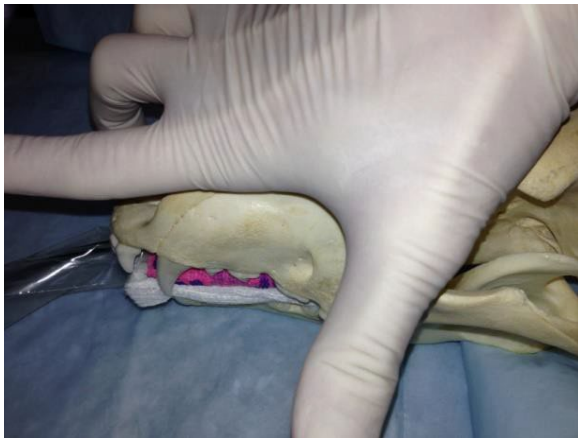

SENSOR PLACEMENT AND TIPS FOR DIFFICULT VIEWS ON THE CANINE PATIENT

Maxillary Canine View

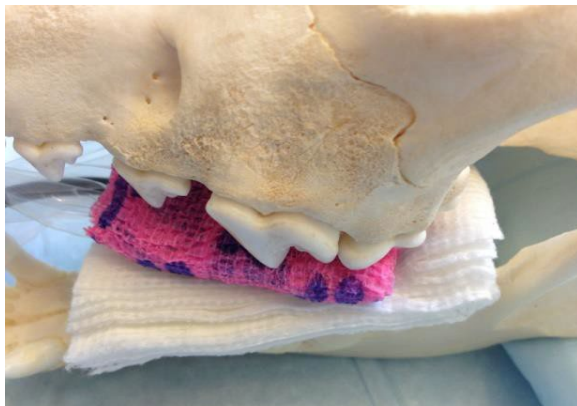

Sensor is parallel to the palate and will sit just inside the crown of the canine tooth. Do not allow the sensor to fall too far inside the crowns of premolar one and two.



Make a 90-degree angle with your thumb and index finger. Place your thumb on the palate in front of the eye and run your index finger up midline. Drop the tube head down into the 90-degree angle you created with your fingers. Make sure you are not coming in perpendicular to the tooth.

Maxillary Fourth Premolar



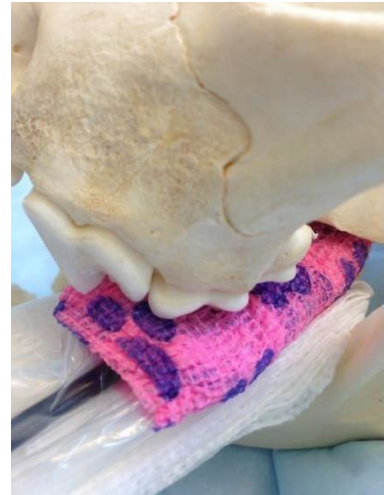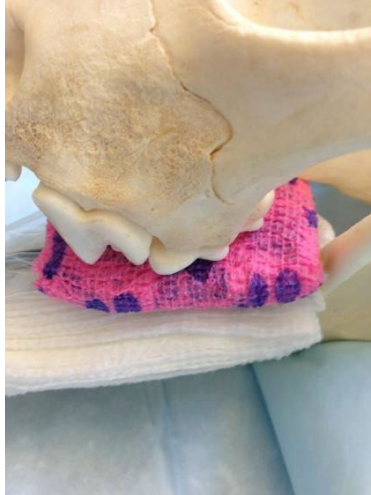
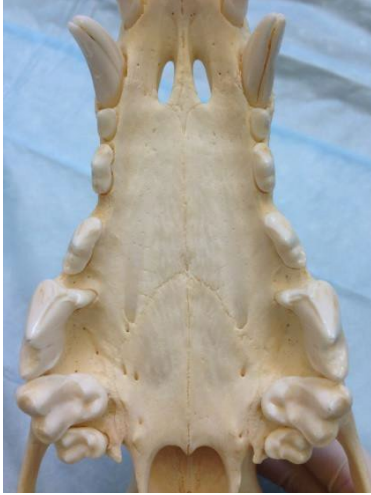Place the back of the sensor on the first molar. Make sure the crown of the third and fourth premolar is resting on top of the sensor.

The landmark for the maxillary fourth premolar is the eye. Start by centering the tube head over the eye, and then rotate the tube head caudal to rostral so that the side of the tube head is resting slightly behind the lateral canthus (corner of the eye).

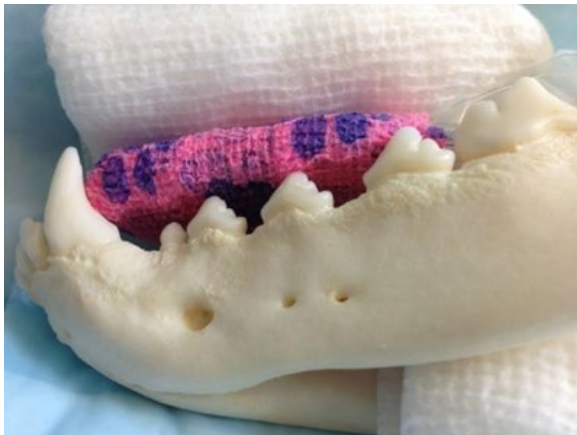This view should nicely separate the three roots. The root in the middle will be palatal.

Maxillary Molar One and Two

Notice how molar one and two curve inward. You may want to slightly diagonal the back of the sensor inward to make sure you do not miss the apices of those two molars. The tube head should already be in perfect position from the previous view.



Mandibular First and Second Premolar

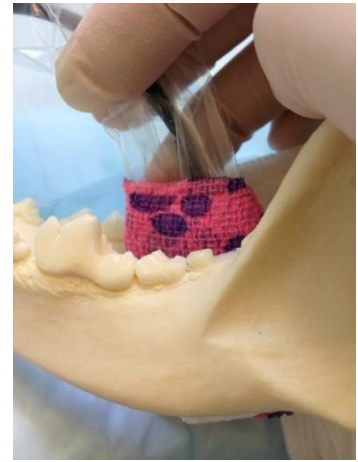
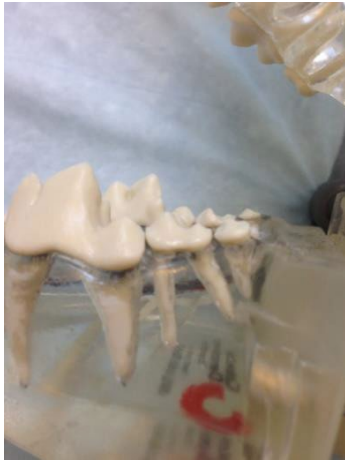

This view is difficult because the symphysis prevents you from taking the parallel technique (like the rest of the mandibular views). It is necessary to place the sensor in the mouth so that it is parallel to the symphysis and the crowns of the mandibular first and second premolar are touching the edge of the sensor.

Start with the tube head parallel to the sensor and symphysis. Look at the tube head angle and increase the angle 25-30 degrees.

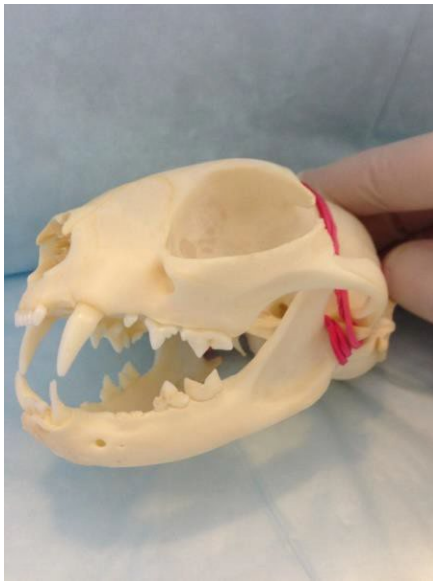
Mandibular Third Premolar

Notice how high the third molar sits. It is often missed. Wrap a gauze square around the sensor to prevent the sensor from floating around in the mouth from the blood and saliva. Turn the sensor vertical so the cable is towards the palate. This is a parallel technique view (parallel to the sensor). You may want to position the tube head a little behind the third molar as to sneak up on it from behind.



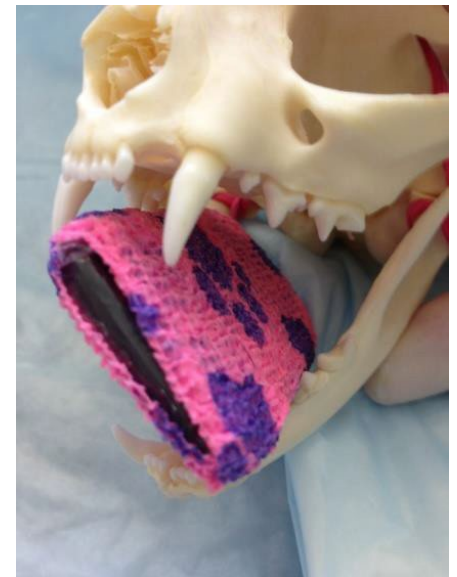SENSOR PLACEMENT AND TIPS FOR DIFFICULT VIEWS ON THE FELINE PATIENT

Maxillary Cheek Teeth

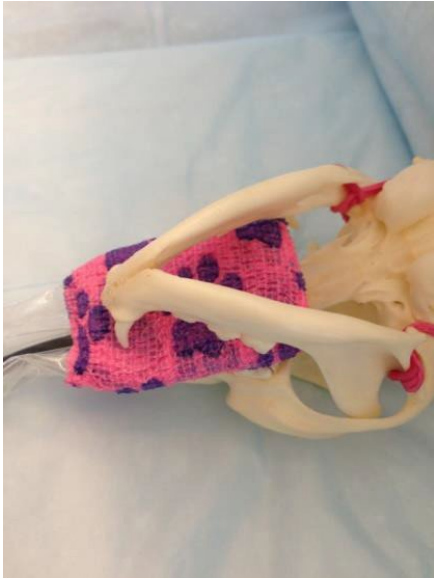


There is only one challenging view on the feline patient and that is the maxillary cheek teeth. The zygomatic arch sits on top of the premolars and molar and can make it difficult to evaluate those tooth roots.

The sensor will be diagonal between the upper canine and opposite lower canine tooth. The sensor is positioned in the picture below to acquire the left cheek teeth. The tube head will be pointed perpendicular to the cheek teeth and eye. It will sit slightly higher than normal.

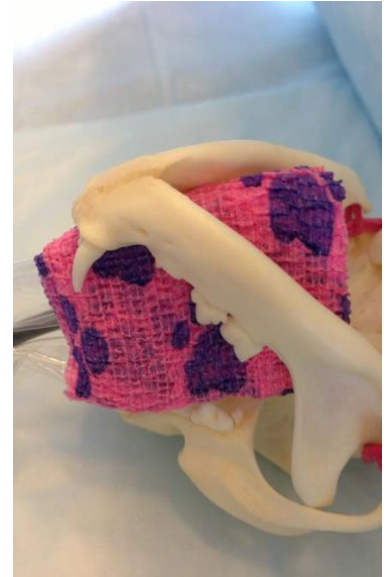

Mandibular Premolars and Molar



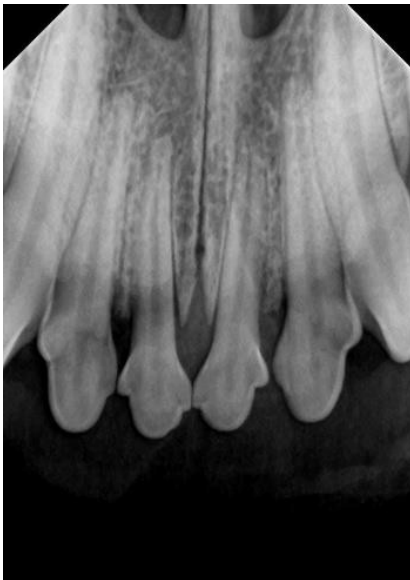You will either get all the premolars and molar in one shot or you may need two. The symphysis makes it difficult to capture the third premolar. With the patient in dorsal recumbency, rotate the tube head off to either side and point directly at premolar three, four and molar one.

If you do not get all the remaining teeth in this view, chances are you missed the distal root of the molar. Rather than making more attempts at the



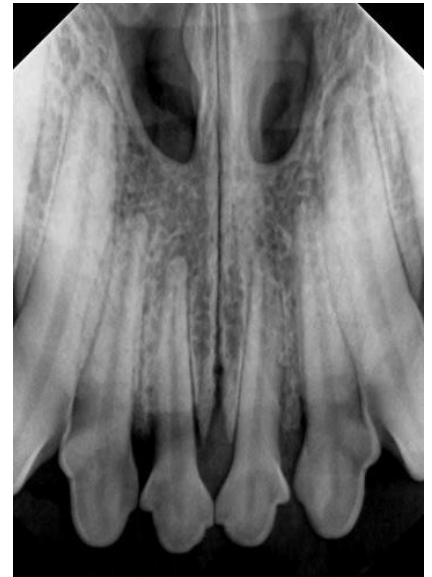
previous technique, flip the sensor so that it is parallel to the molar and point the tube head parallel to the sensor-straight on. This view will get you the last molar, but you will most likely miss the third premolar (due to the symphysis).

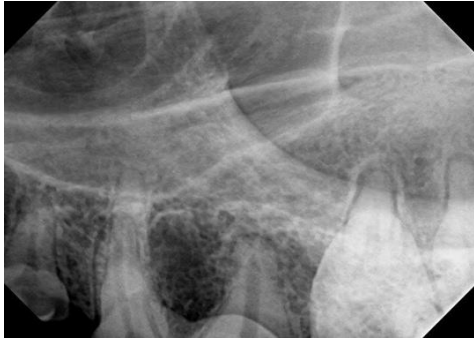COMMON POSITIONING ERRORS AND CORRECTIONS



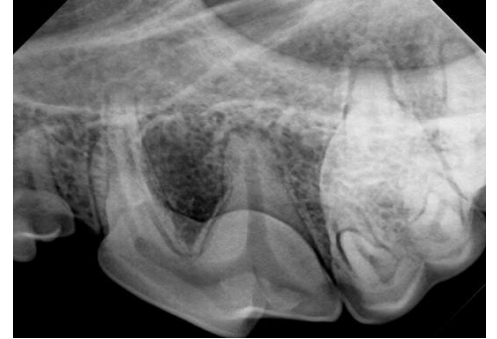This image (on the left) of the incisors is just missing the apices of the lateral incisors. There is a lot of the sensor outside of the patient's mouth (black area). Instead of moving the tube head, push the sensor further in the mouth so that the tips of the crowns rest on the edge of the sensor.

The opposite holds true. If you acquire an image and you are unable to evaluate the alveolar bone around the crown of the tooth, you will need to pull the sensor towards you. Sometimes the sensor can fall inside the crowns instead of resting on the sensor.



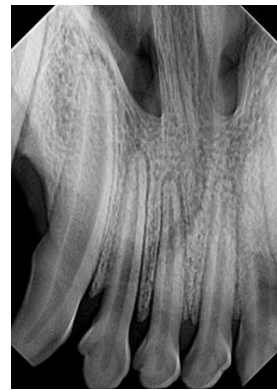
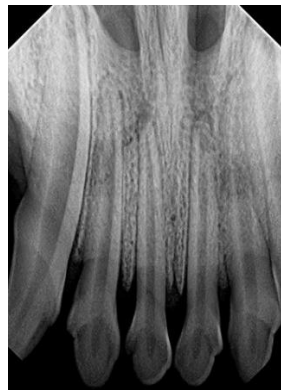

This image is of the upper fourth premolar. As you can see, the bone surrounding the crown of the tooth is not visible. The sensor has slipped inside the crown of the tooth. Simply pull the sensor towards you.



Elongation and Foreshortening

A little elongation or foreshortening is acceptable as long as you are able to clearly identify the structures of the tooth. As a rule, if the tooth root appears long, redirect the tube head so it is pointing at the sensor. If the tooth root appears foreshortened, redirect the tube head toward the patient. On the maxilla, you will increase the angle if the roots are long and decrease if the roots are short.



When to move the tube head vs the sensor

Most images acquired that are not diagnostic are due to incorrect sensor placement, however, if you get an image with a "cone cut," that is when you need to move your tube head towards the white out area to correct it. Do not change the angle of the tube head.

